



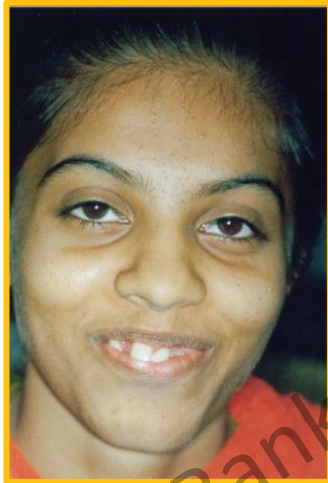PULSETM
Orthodontia

Treatments & Case Studies

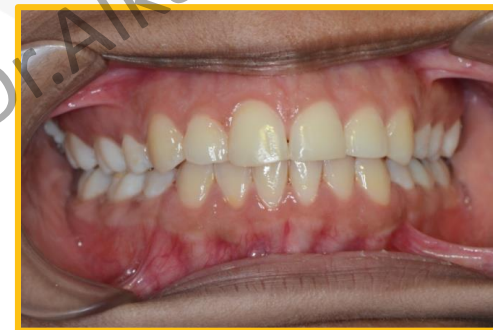
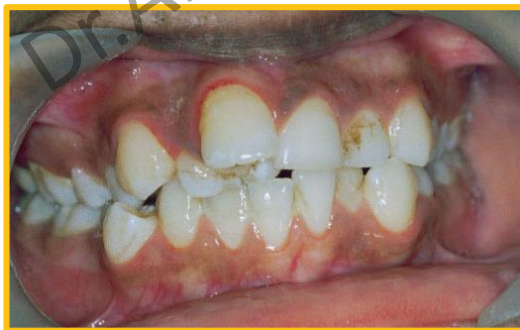WWW.PULSEORTHODONTIA.COM

LONG TERM FOLLOW-UP OF ALL 4 PREMOLAR EXTRACTION CASE:

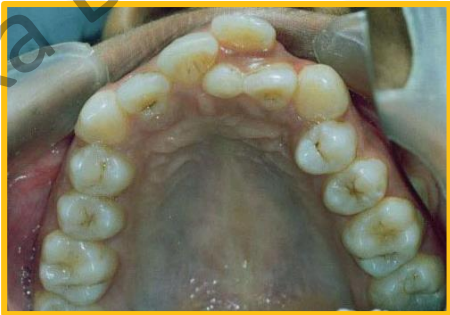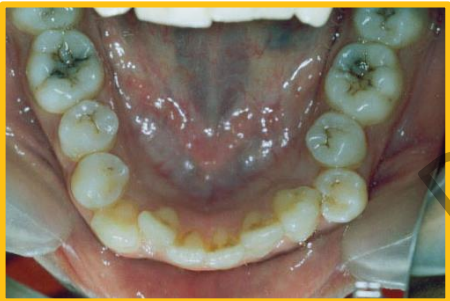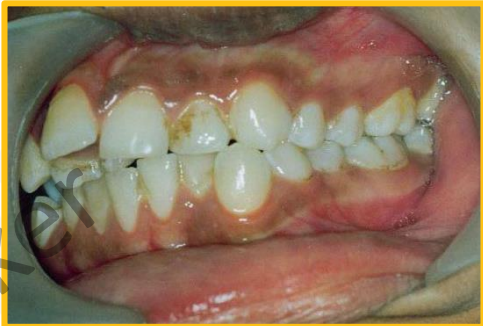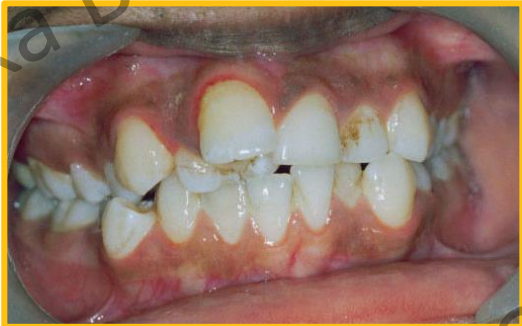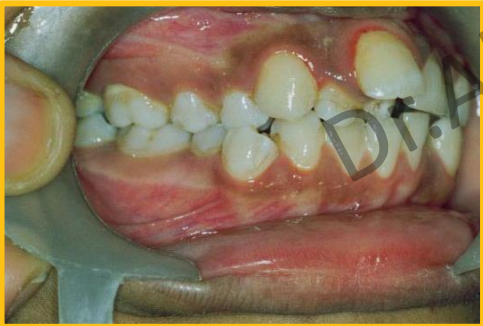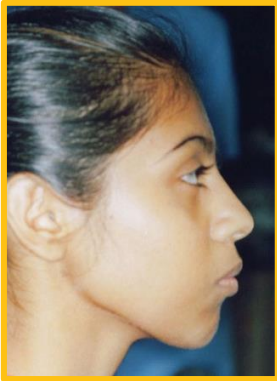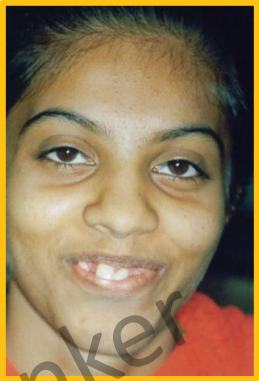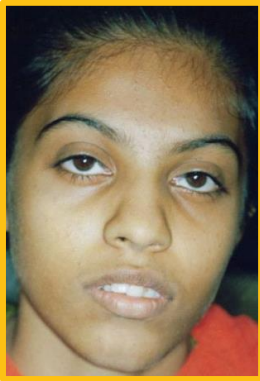Before



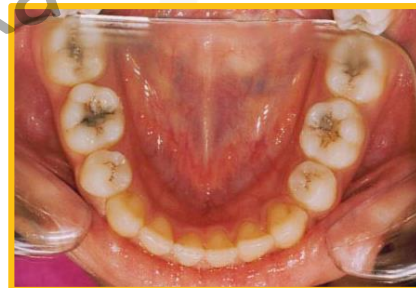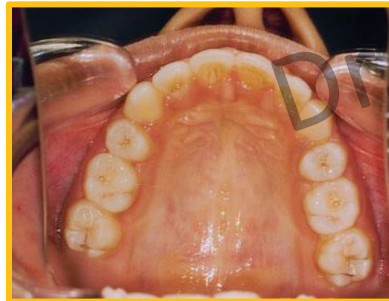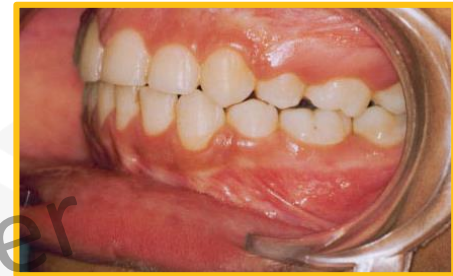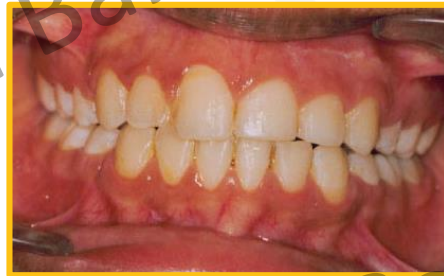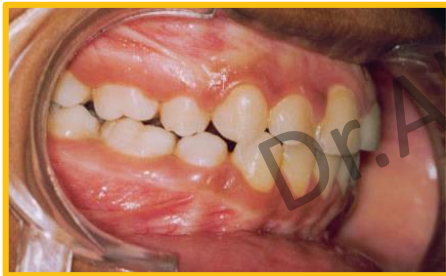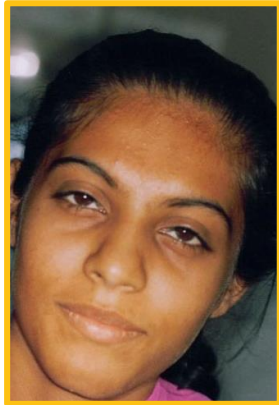After



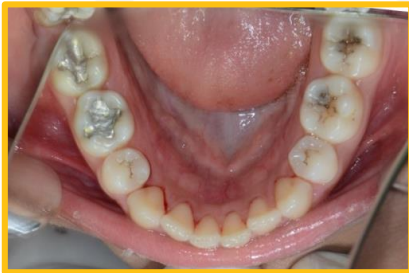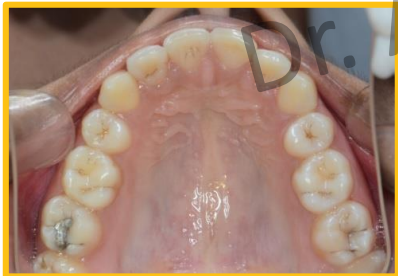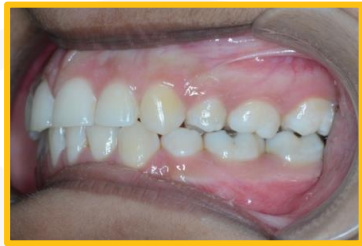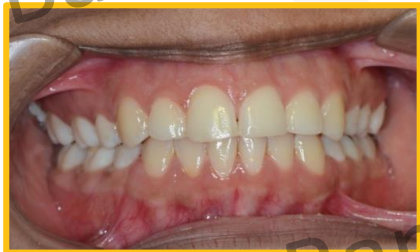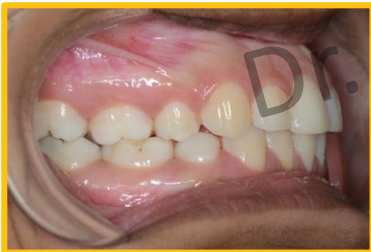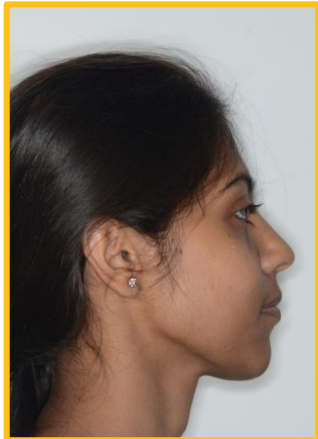BEFORE TREATMENT



AFTER TREATMENT



12 YEARS AFTER TREATMENT!



CUTE LITTLE BABY NAMRATA'S FIRST DENTAL VISIT!



Long term follow-up of all 4 premolar extraction case:

When there is bimaxillary protrusion, incompetent lips, severe crowding and anchorage requirements are higher. In such cases, it's difficult to maintain torque. Please see our patient; 12 years after treatment, where torque, smile and extraction spaces have been well maintained.



PULSETM
Orthodontia

Treatment &
Case Studies

WWW.PULSEORTHODONTIA.COM

