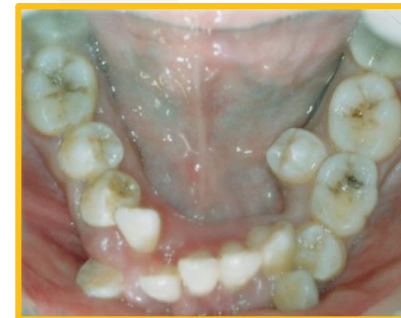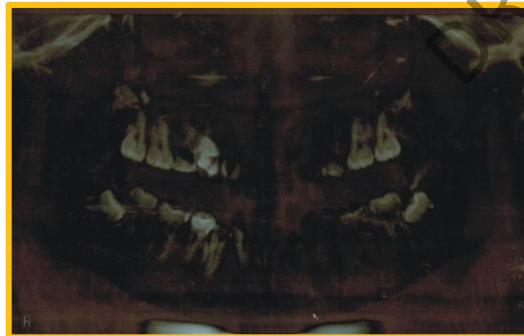

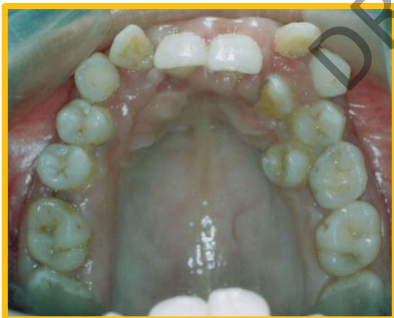
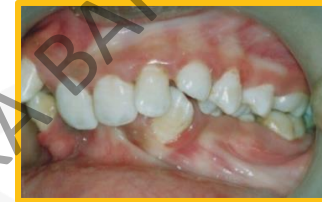
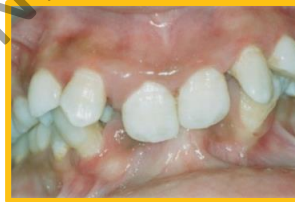
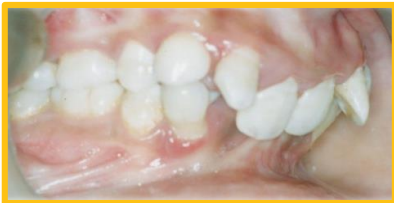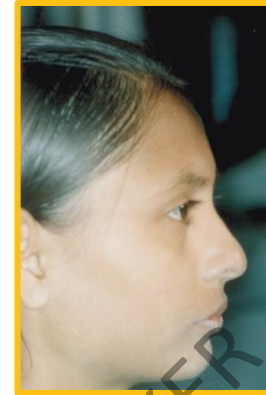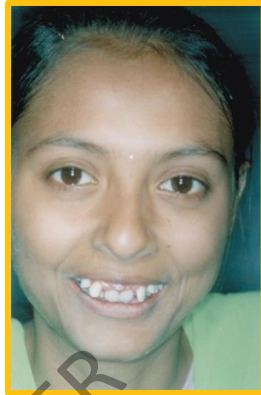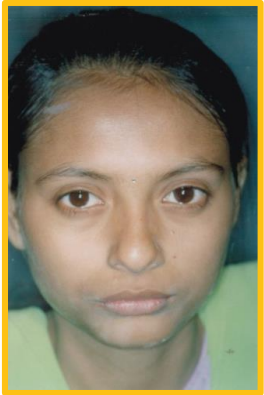Treatments & Case Studies

WWW.PULSEORTHODONTIA.COM

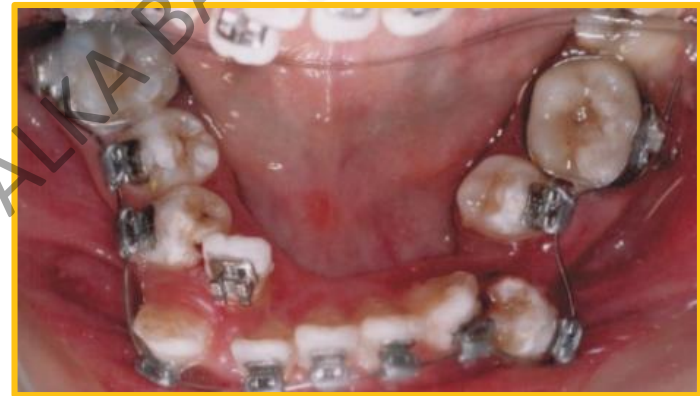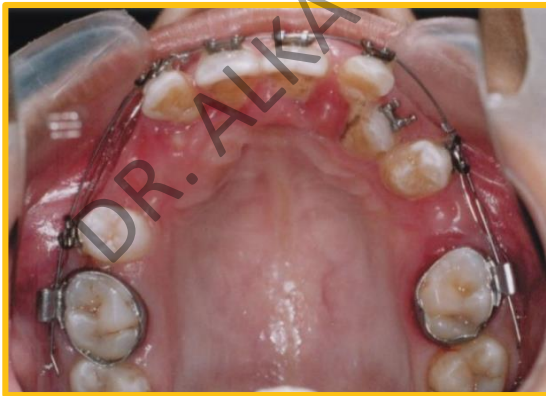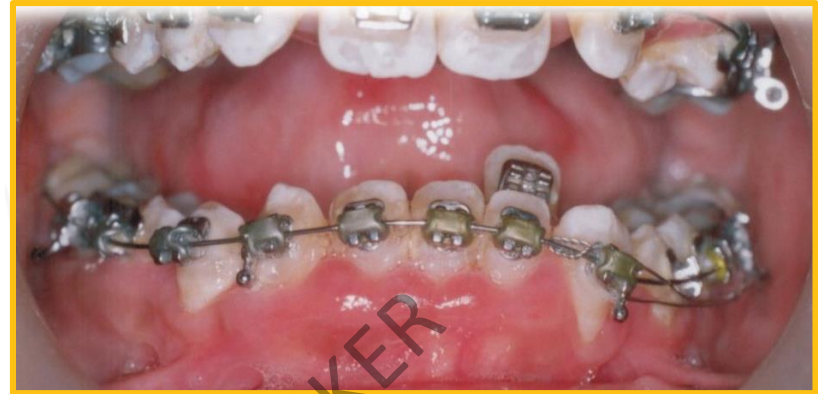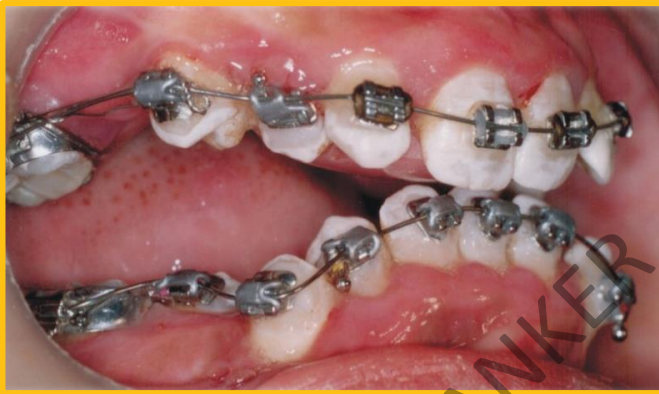PRE-TREATMENT



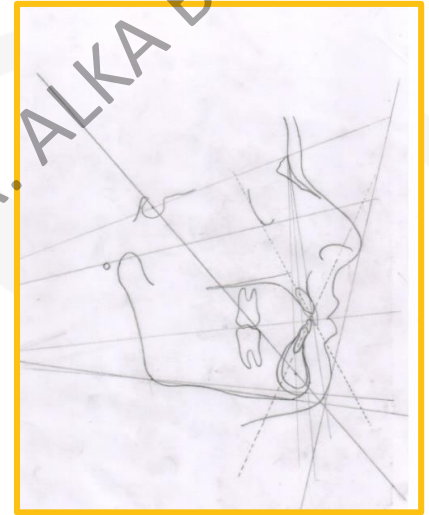
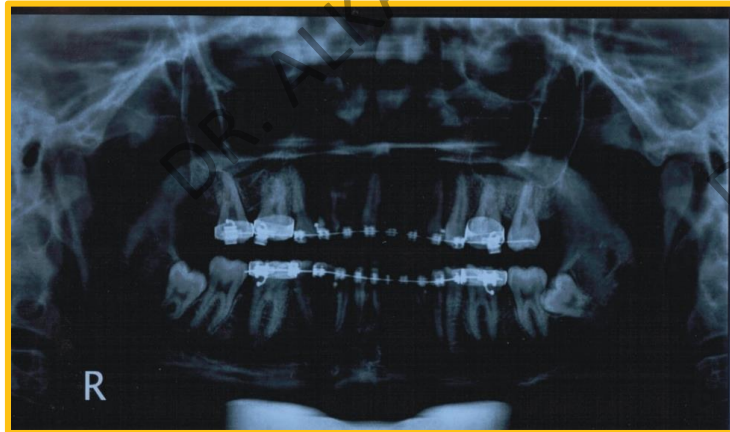
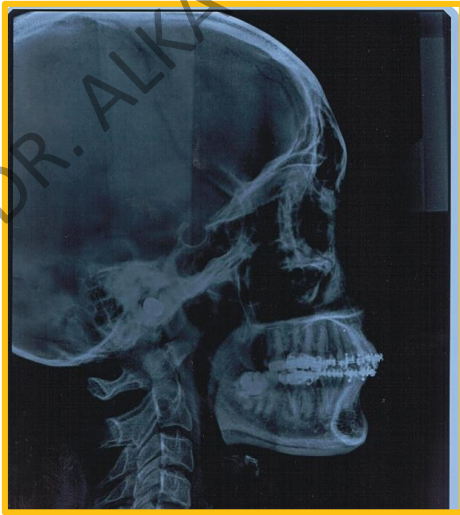
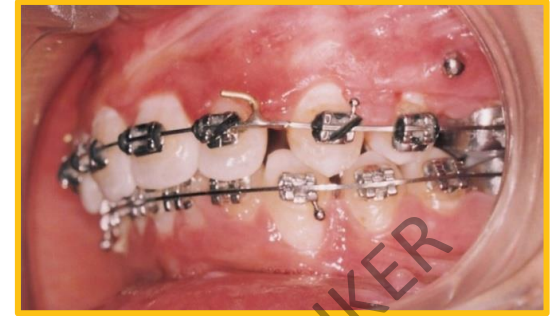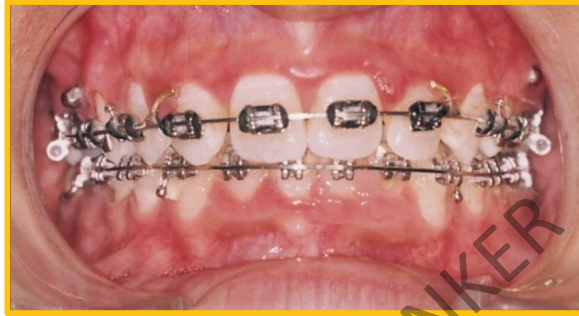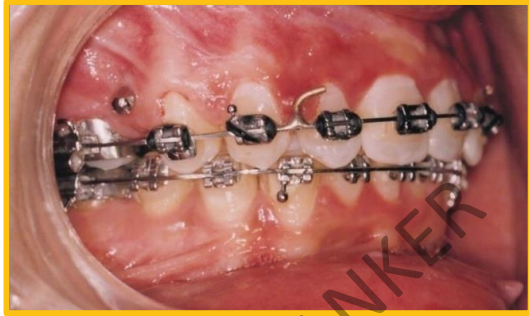DR. ALKA BANKER

DR. ALKA BANKER

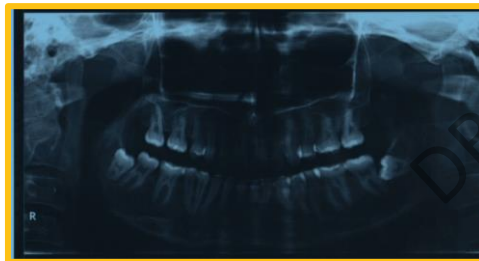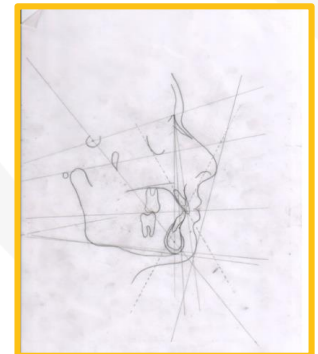

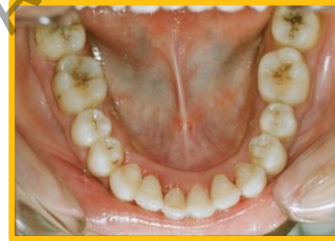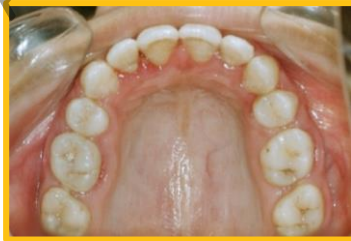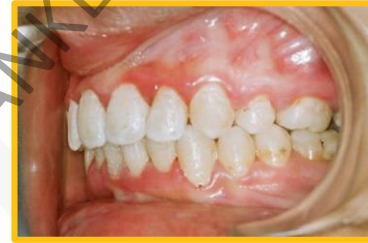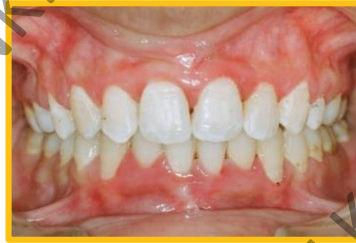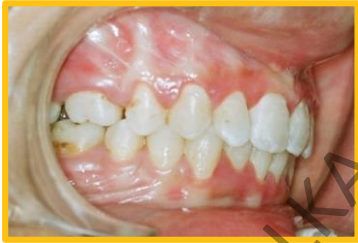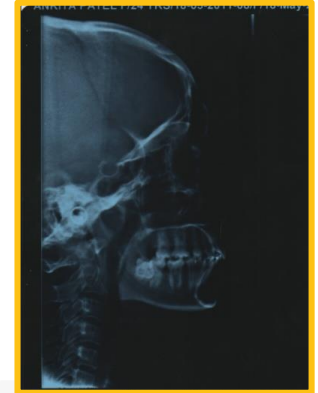MID TREATMENT-1



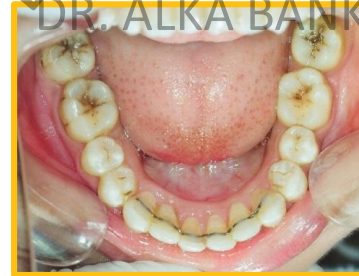
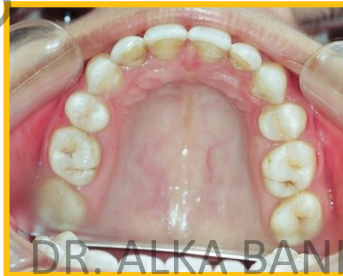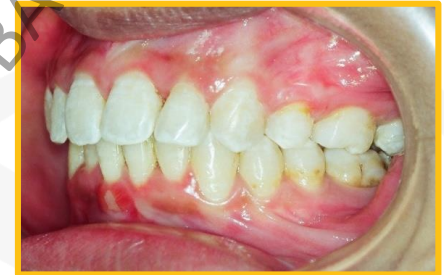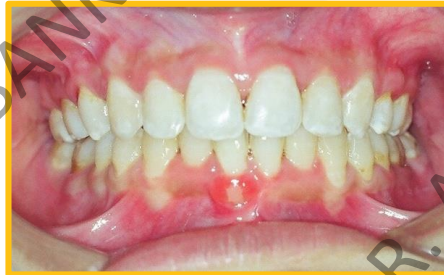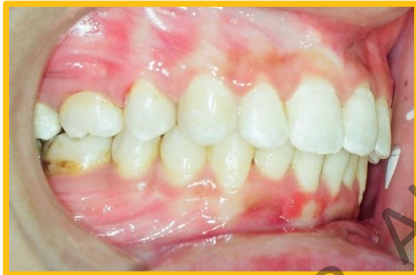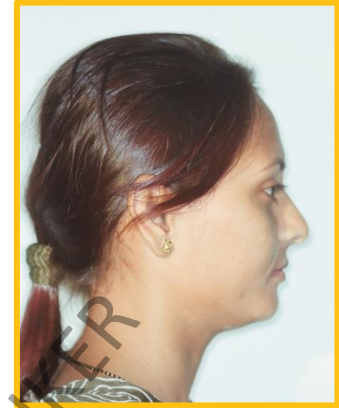WITH TADS (MINI IMPLANTS)



POST- TREATMENT



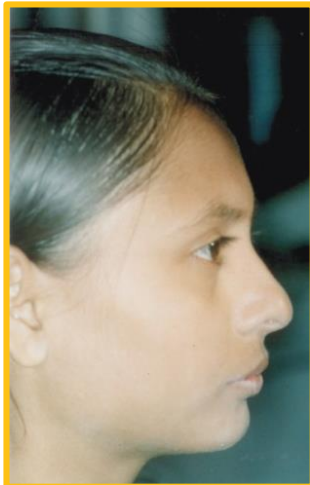3 YEARS POST TREATMENT FOLLOWUP!



Before treatment



After treatment



Notes: A patient of age 20 years with a Class II division 2 malocclusion, deepbite, severe crowding & gummy smile was treated with TADs, upper bicuspid extractions and SLIDE modules.

Despite severe crowding in lowers, extractions in lower arch was avoided.

The SLIDE module is a new attachment which converts the conventional friction slot into a low friction slot.

Note the profile, smile and gum health post 3 years of retention.



Treatments &
Case Studies

WWW.PULSEORTHODONTIA.COM