



# Treatments & Case Studies

[WWW.PULSEORTHODONTIA.COM](http://WWW.PULSEORTHODONTIA.COM)

A case of a 12 years old male presenting with a class II division 1 malocclusion with deepbite, crowding and narrow v shaped palate.

Treatment was done with SRME (Semi Rapid Maxillary Expansion) for 4 months.

Remodelling of palatal vault was done which was stable till 3 years post retention.

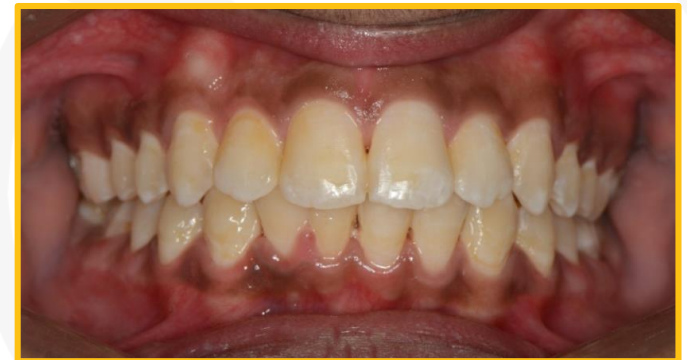
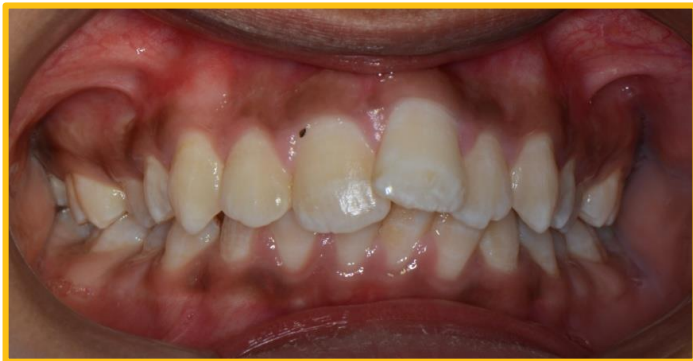Only 3 archwires were used in fixed appliance. Class II corrected by itself due to change in transverse dimension from “V” shape to broad “C” shape.

**PERFECT smile, occlusion & profile were obtained at the end of retention!!!**

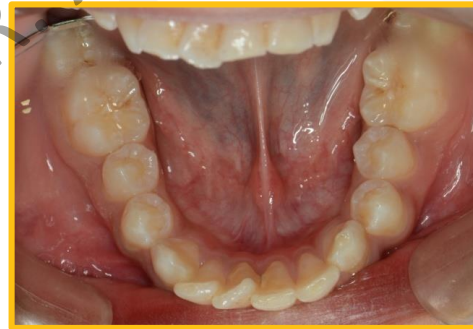
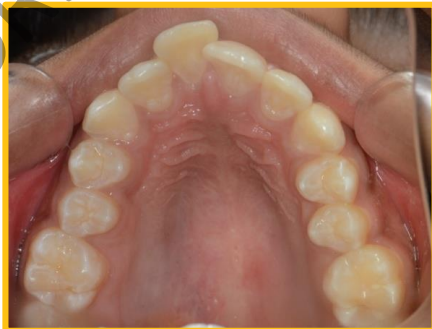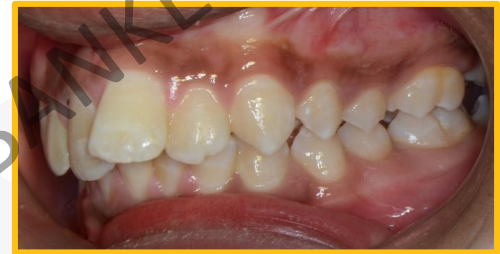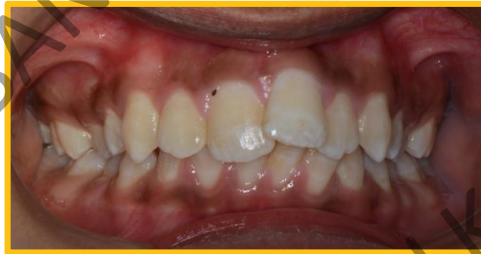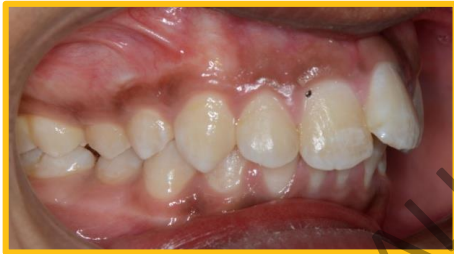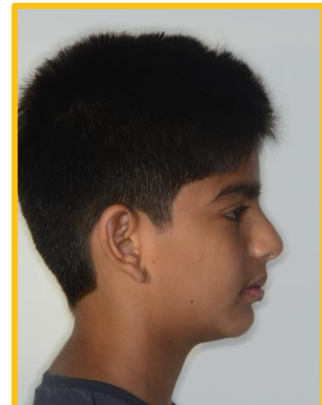Before



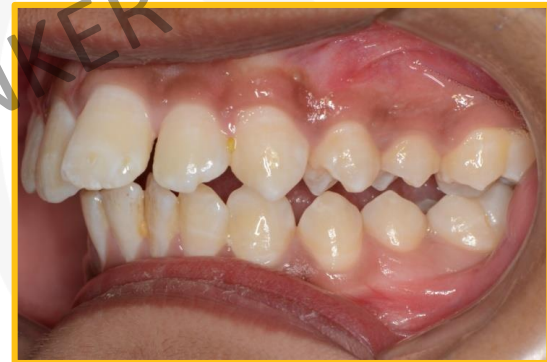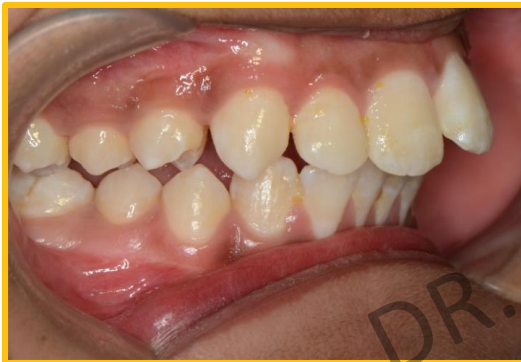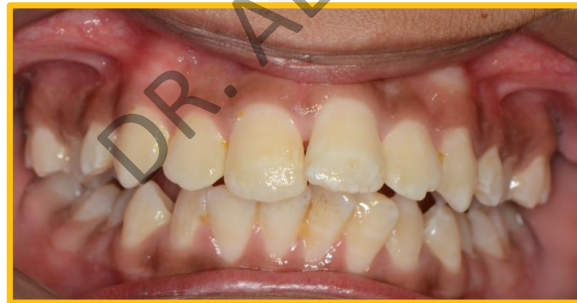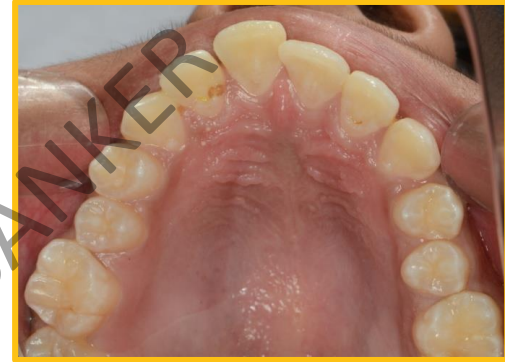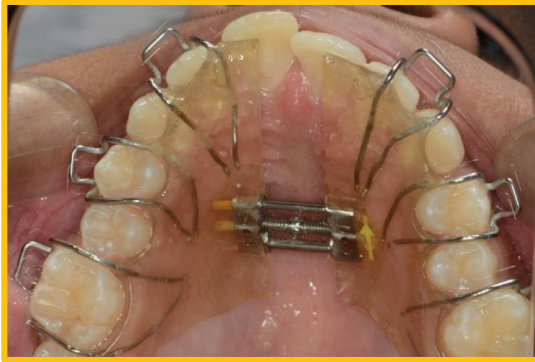
After



# PRE-TREATMENT

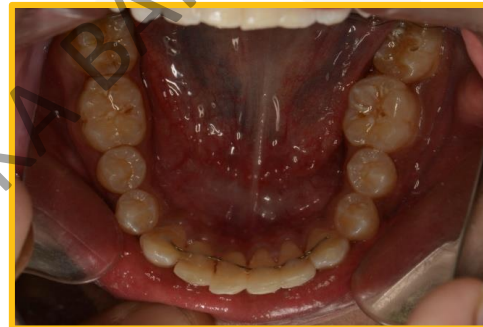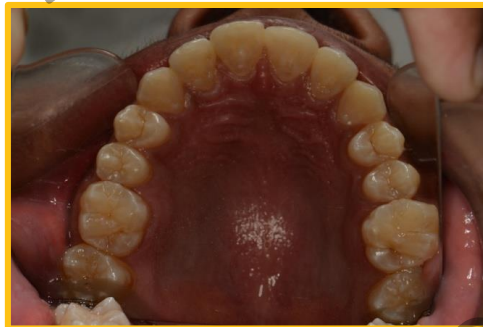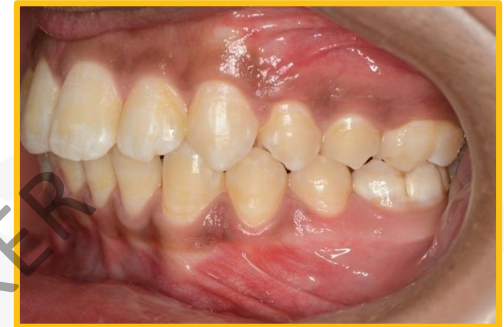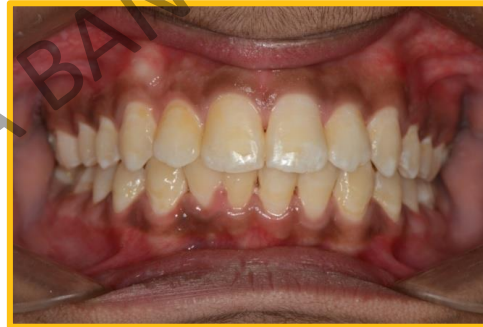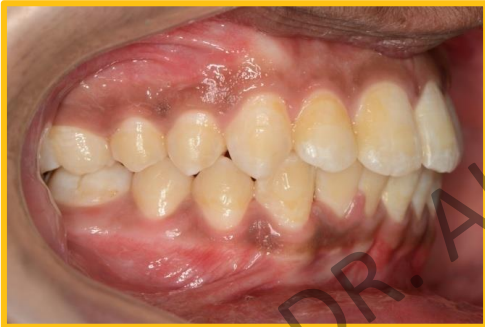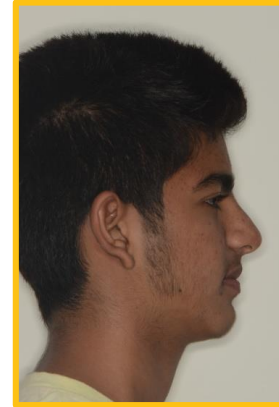



# AFTER EXPANSION WITH SCREW PLATE

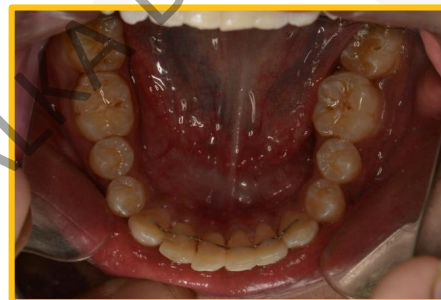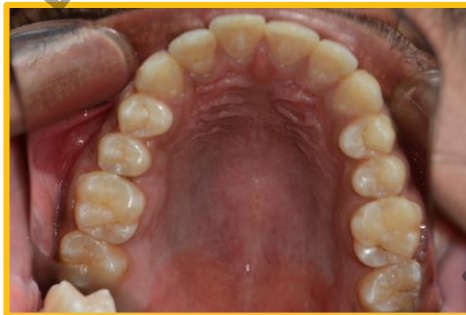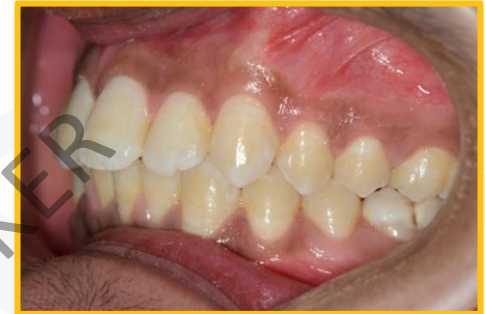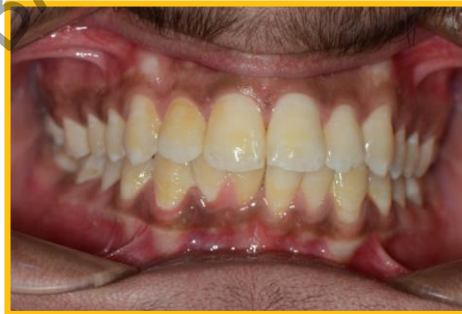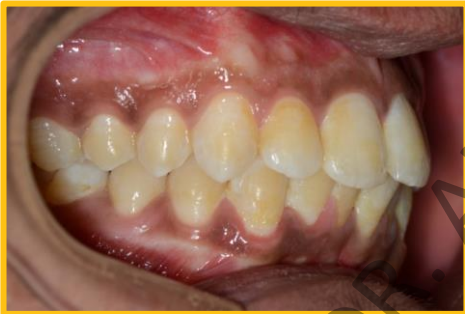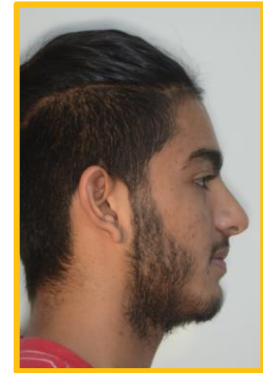




# POST TREATMENT



# 3 YEARS POST TREATMENT !





Treatments &  
Case Studies

[WWW.PULSEORTHODONTIA.COM](http://WWW.PULSEORTHODONTIA.COM)