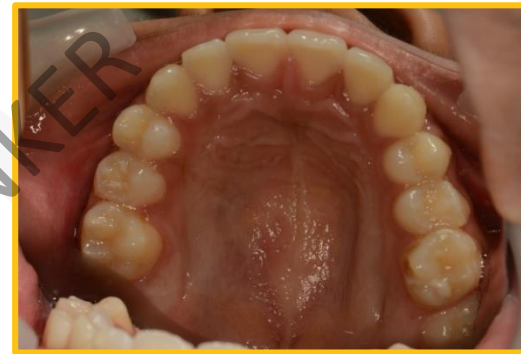
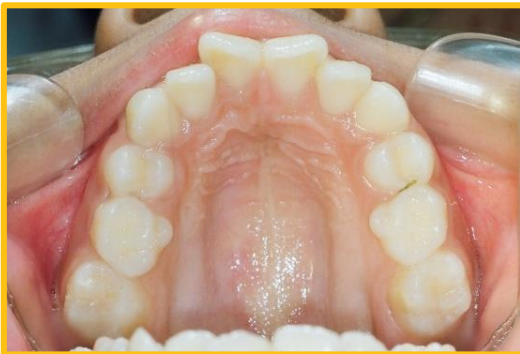


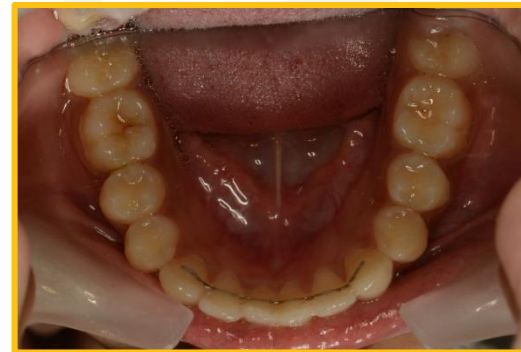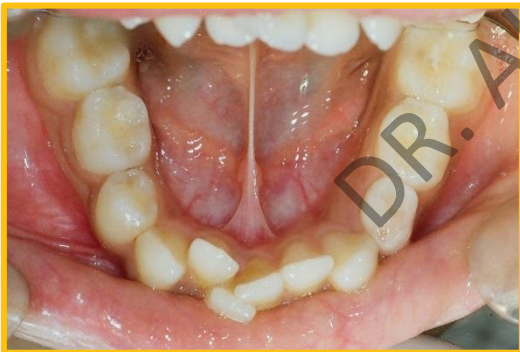Treatments & Case Studies

WWW.PULSEORTHODONTIA.COM



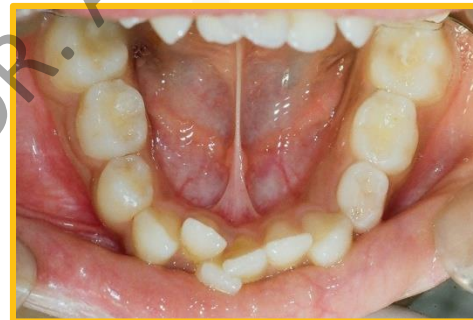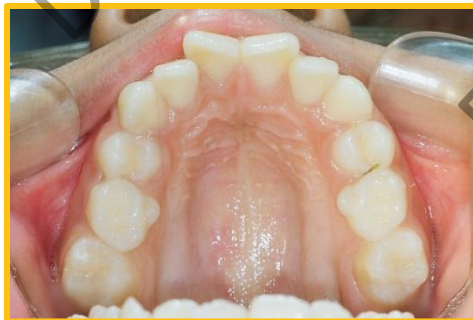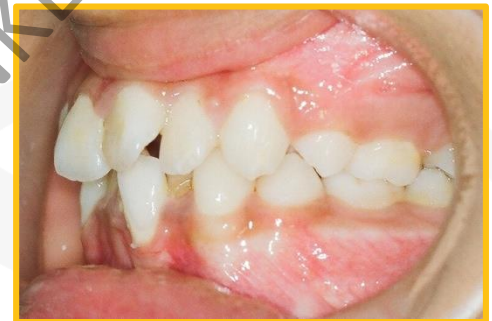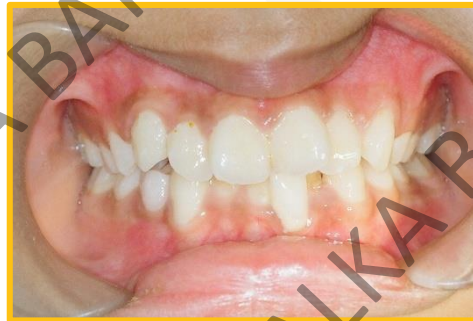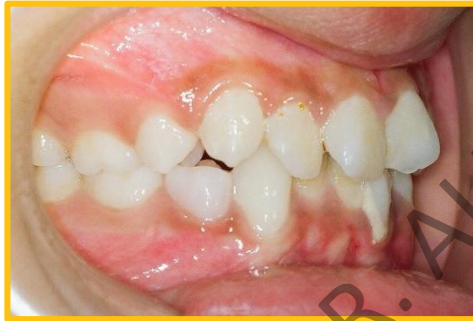UPPER
TEETH



LOWER
TEETH

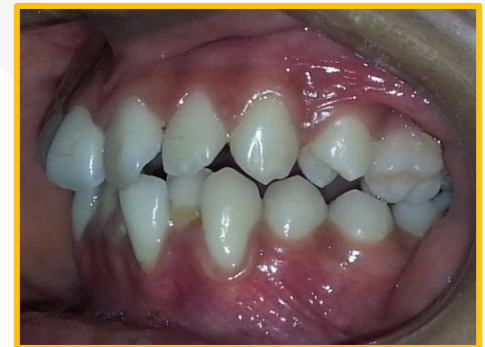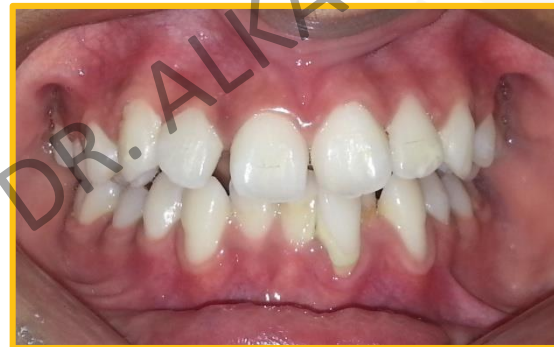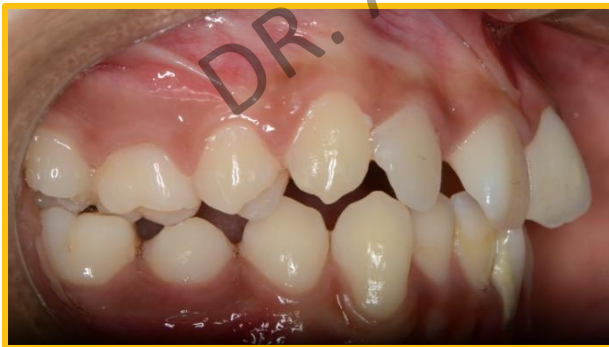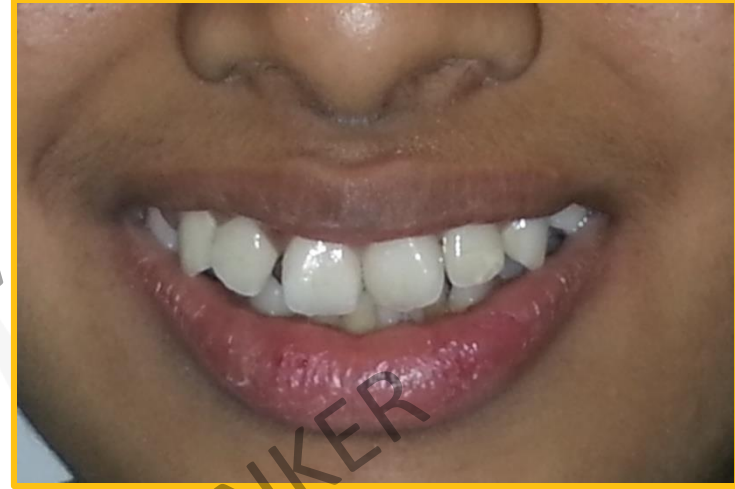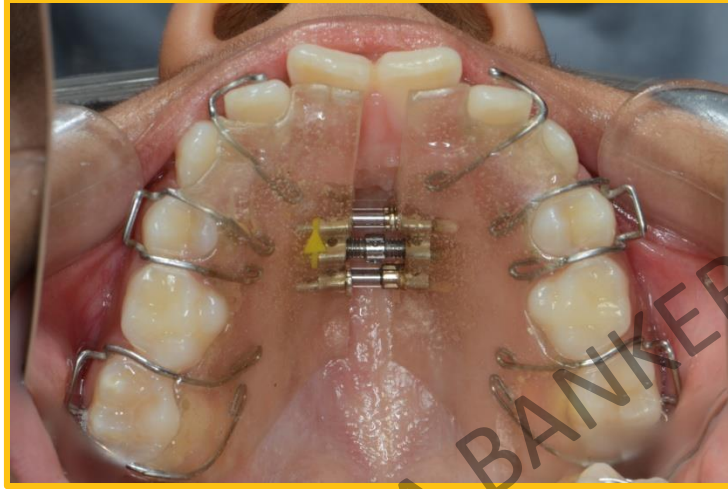DR. ALKA BANSAL

PRE-TREATMENT

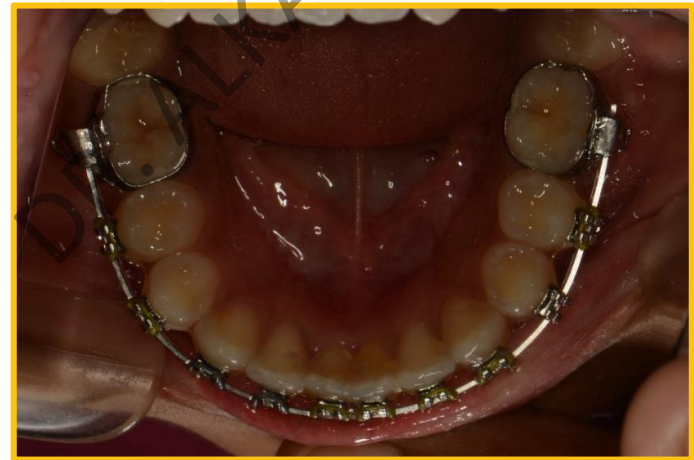
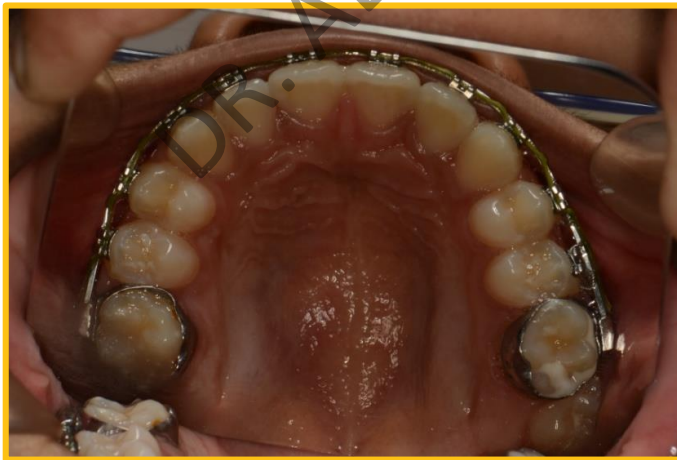
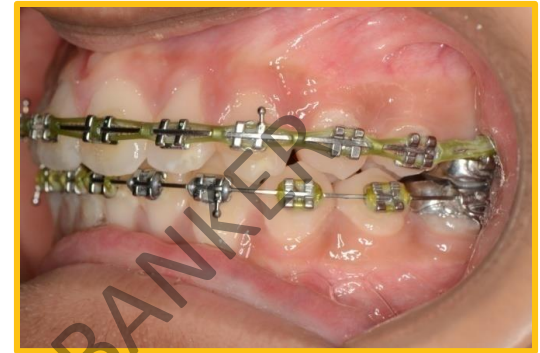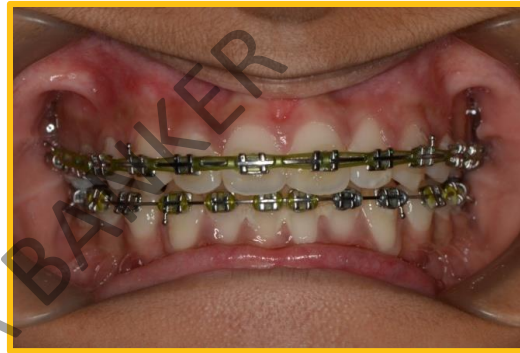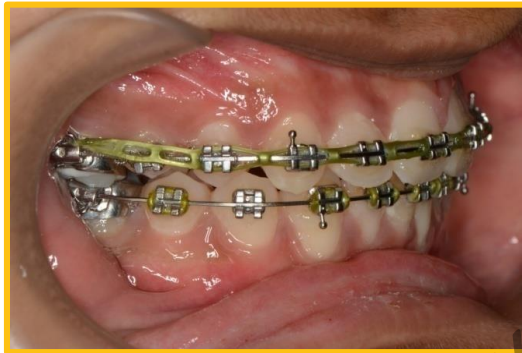DR. ALKA BANKER

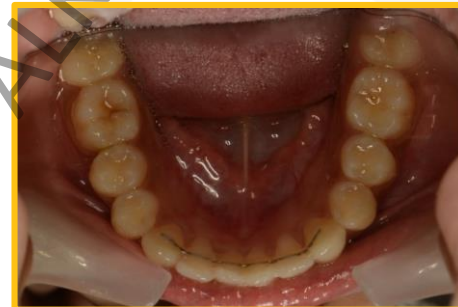
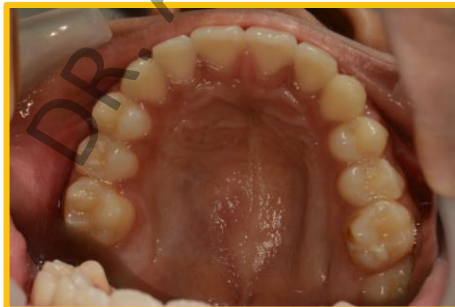
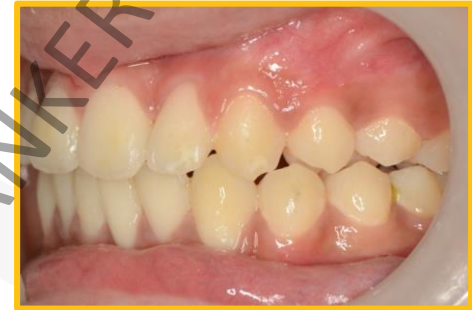
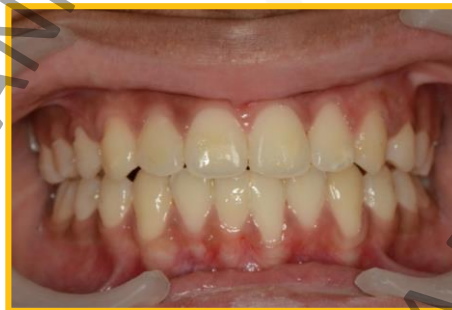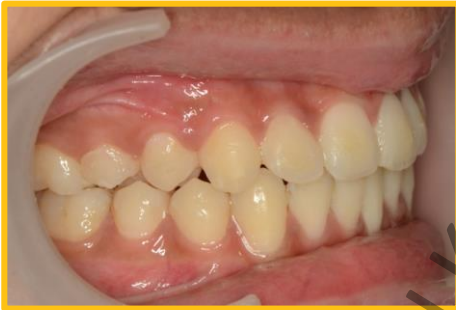AFTER TREATMENT WITH SCREWPLATE APPLIANCE



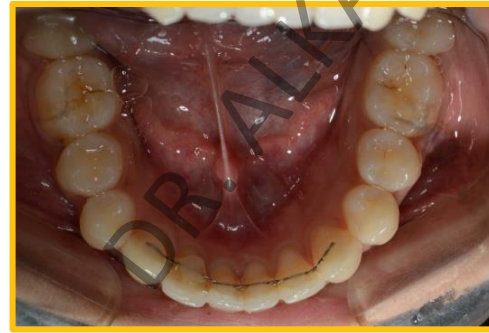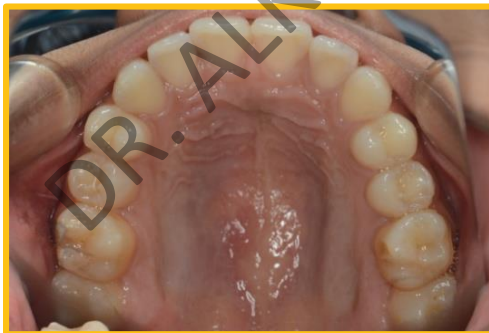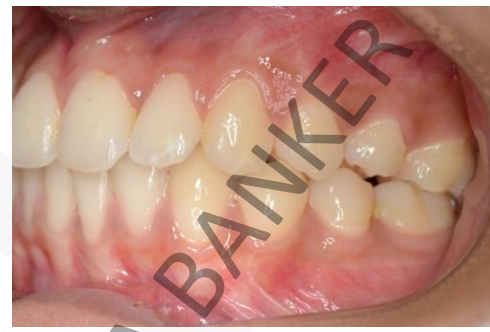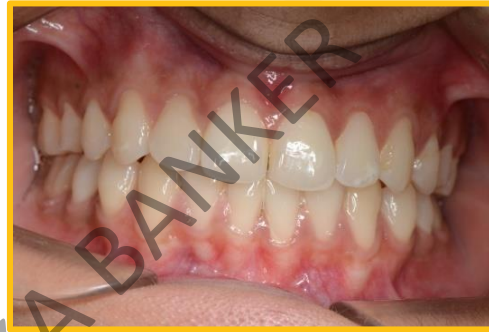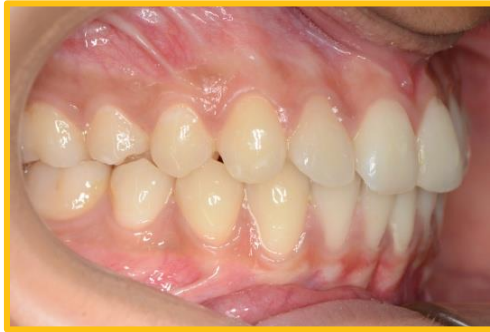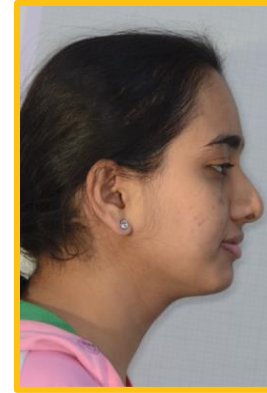
WITH FIXED APPLIANCE



POST TREATMENT



4 YEARS' FOLLOWUP



Notes:

A case of class I malocclusion with severe crowding; treated with Non Extraction treatment protocol along with Semirapid expansion appliance.

A 12 years old female patient came to us with a smile showing very few teeth, both upper as well as lower under developed jaws, resulting in crowding of teeth. She had been advised extraction of 4 teeth by other doctor to make space for crowding to be relieved. Those doctors felt that relieving crowding without removing teeth will make profile even worse and give her protrusive lips.

We used a semi rapid expansion protocol to gain space in lateral direction. We utilized this space to correct crowding by using only two wires in her fixed appliance treatment.

Please see her beautiful smile and well proportioned facial profile after we finished the treatment.

Please also note that occlusion has settled very well 4 years post treatment and her lateral expansion has been maintained.

If your protocol is good ; there is no relapse in transverse direction.

Do you think her face, side profile and smile would have been so good if we had done treatment with extractions???

It's time for all of us professionals to rethink retraction mechanics in orthodontics.



Treatments &
Case Studies

WWW.PULSEORTHODONTIA.COM