



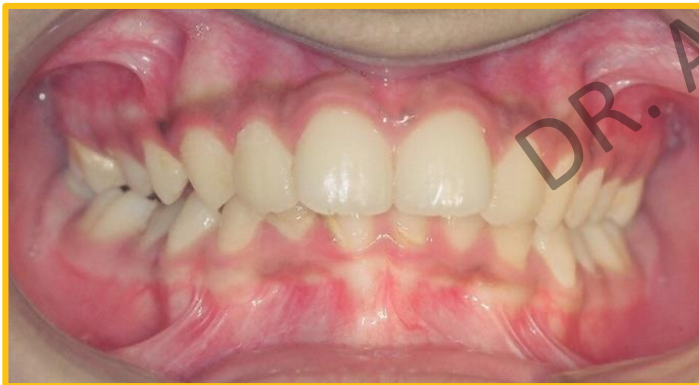Treatments & Case Studies

WWW.PULSEORTHODONTIA.COM

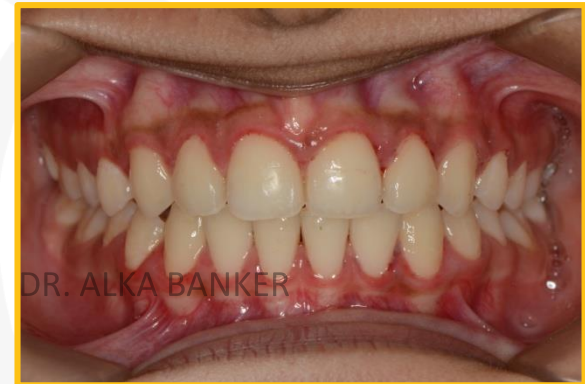BEFORE



AFTER



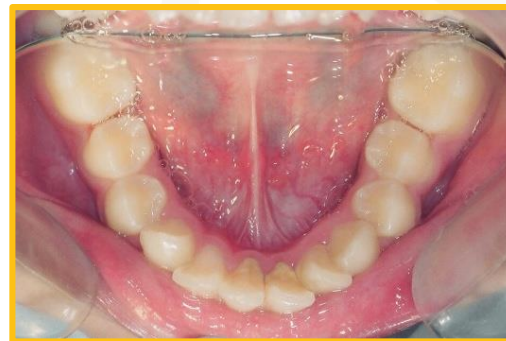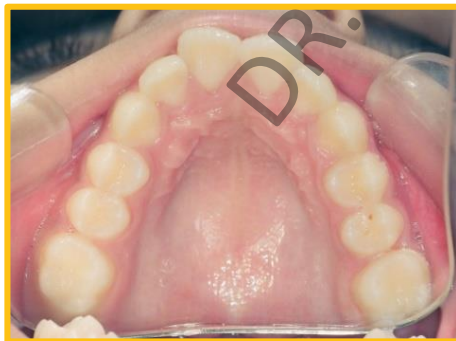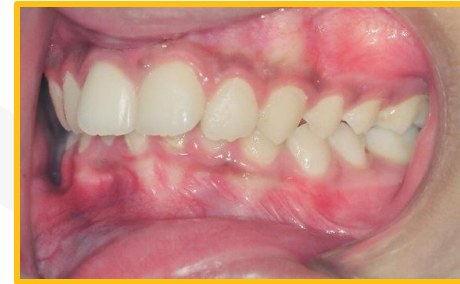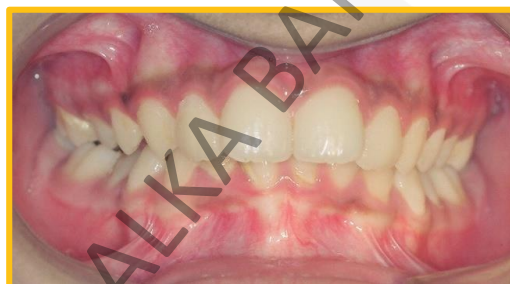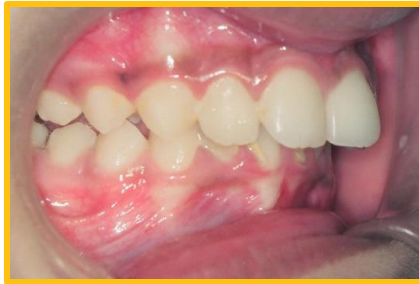PERFECT BITE



DR. ALKA BANKER

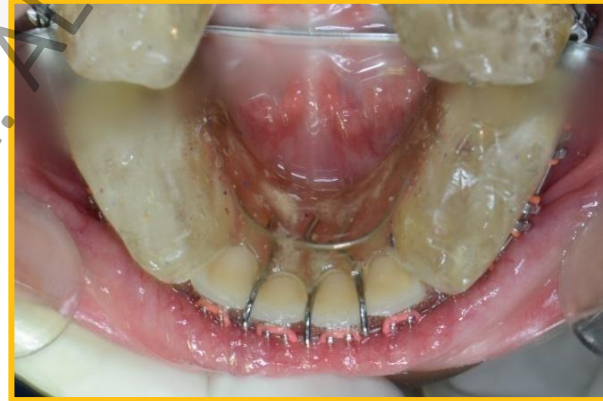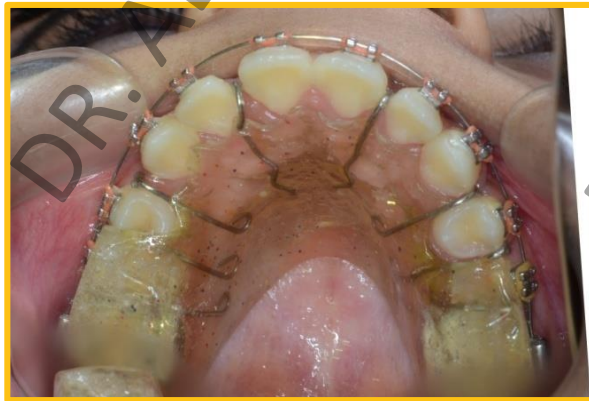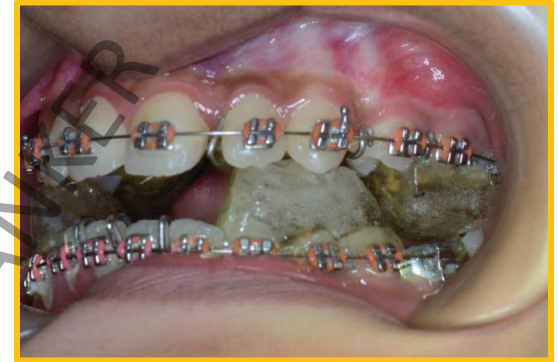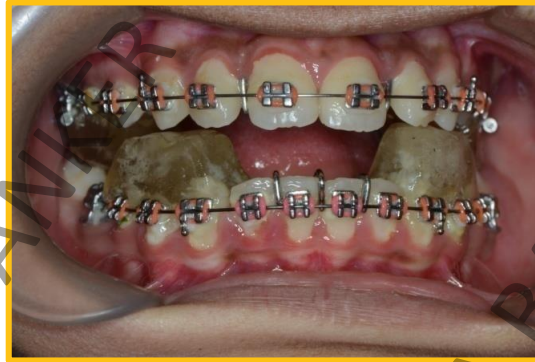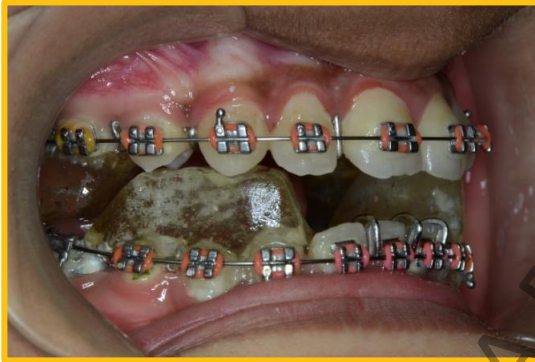
DR. ALKA BANKER

PRE-TREATMENT

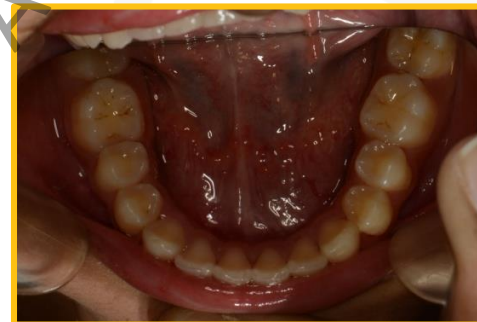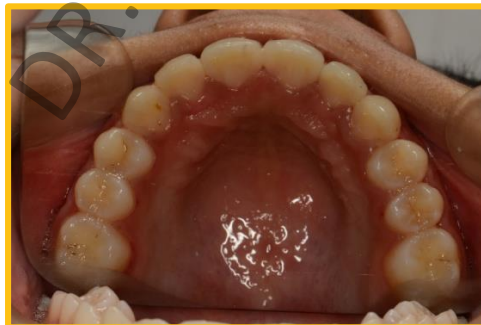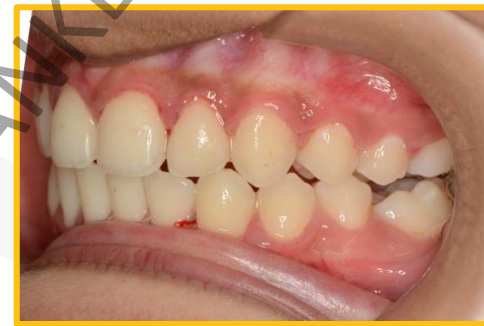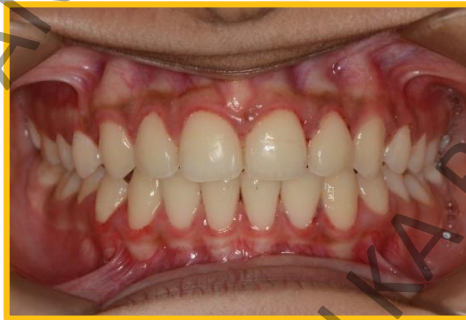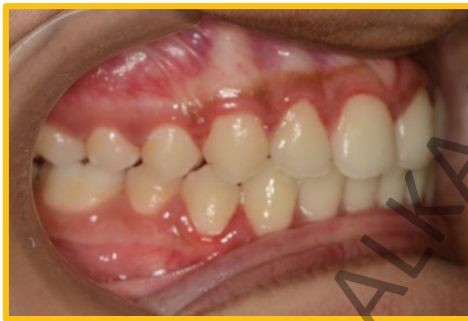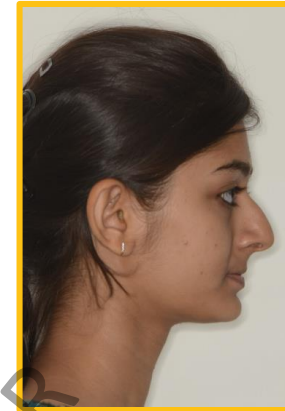


DR. ALKA BANKER

WITH TWIN- BLOCK APPLIANCE



1.5 YEARS POST TREATMENT FOLLOW-UP!!



Notes:

A case of Class II malocclusion treated with twinblock appliance followed by fixed mechano therapy.

A patient aged 13 years came to us with chief complaint of negative smile and protruding teeth. On examination; we found she had a deepbite and endon occlusion, V shaped palate and upper – lower crowding. We also found that she had dish in facial profile with retrusive lips.

We opened up V shaped palate and put her on myofunctional appliance to push her lower jaw forward. Not only we managed to get a beautiful smile, we also managed to open up her bite, palate as well as airway.

Patient now says she breathes much better and does not get tired easily. Protrusive mechanics are a boon for the airway. Always remember “Health before Beauty”.



Treatments &
Case Studies

WWW.PULSEORTHODONTIA.COM