



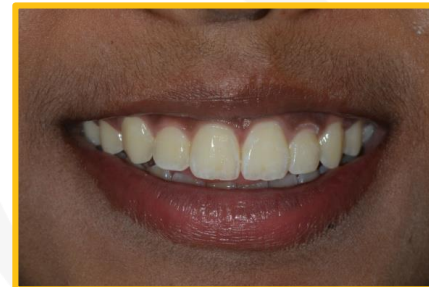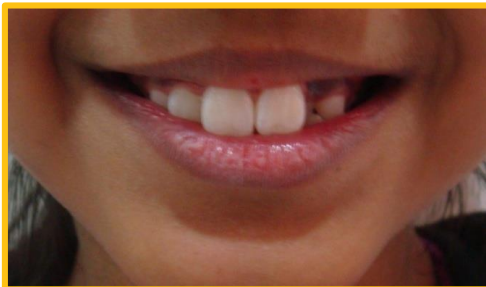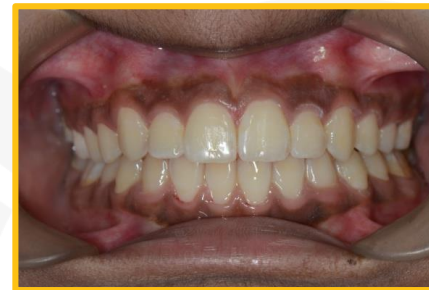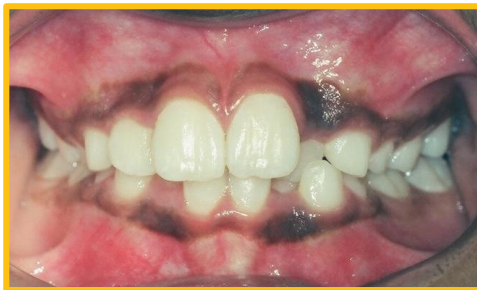Treatments & Case Studies

WWW.PULSEORTHODONTIA.COM

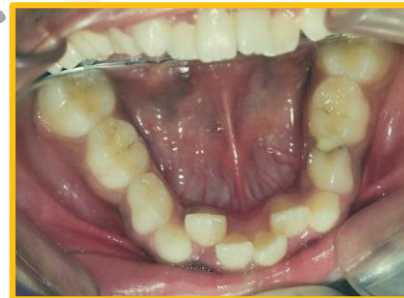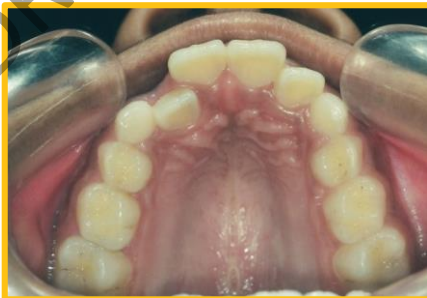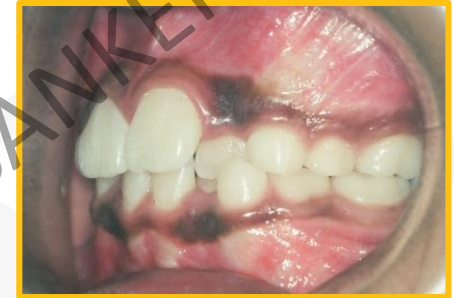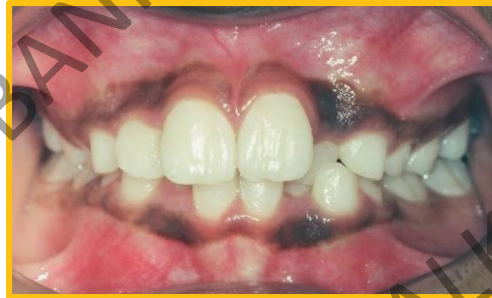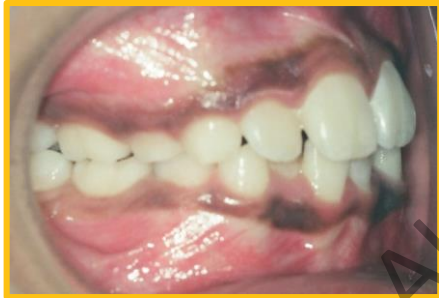Before treatment



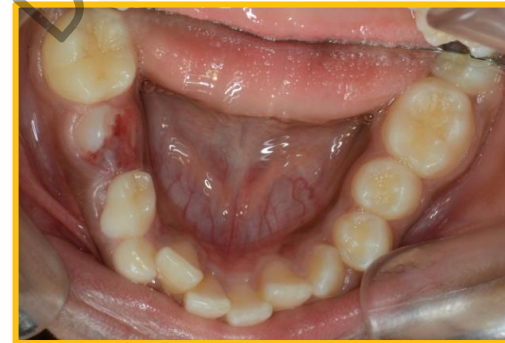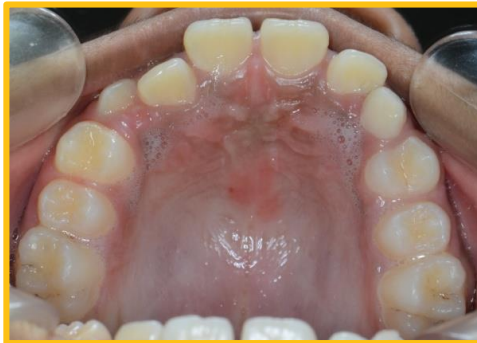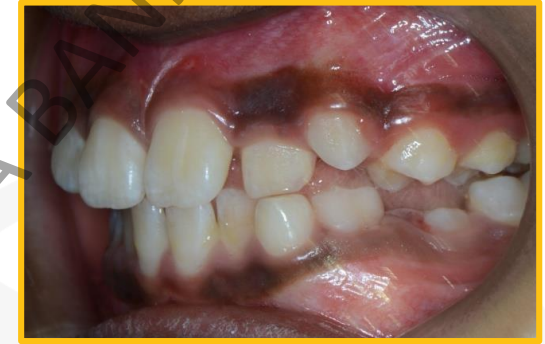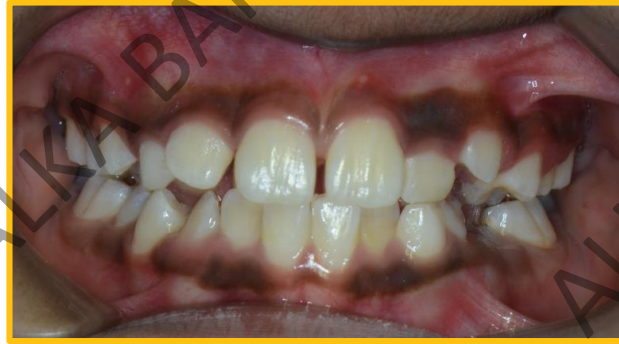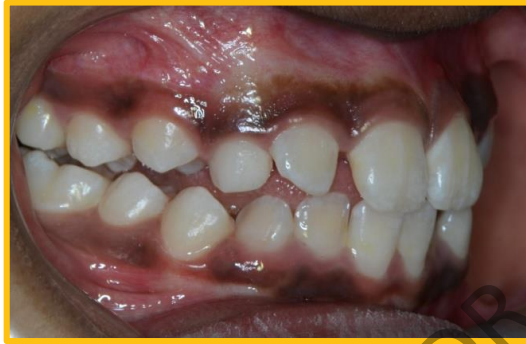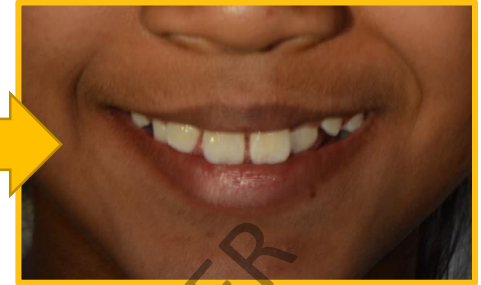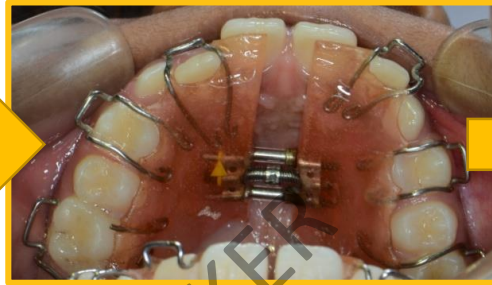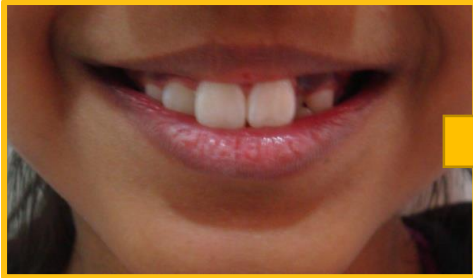After treatment



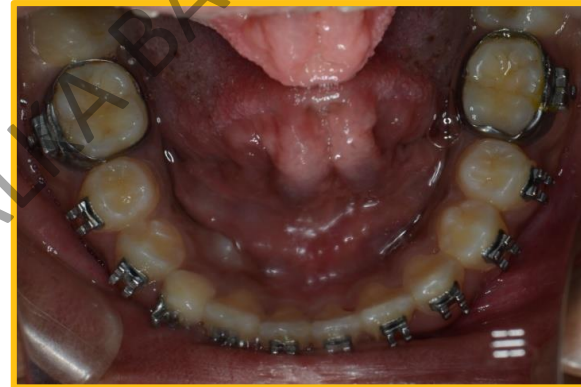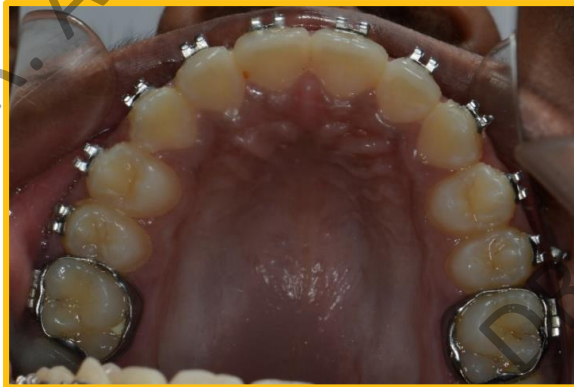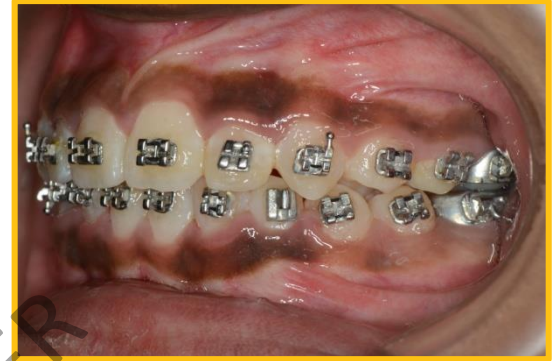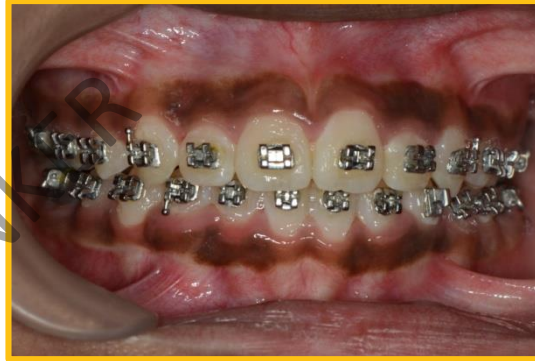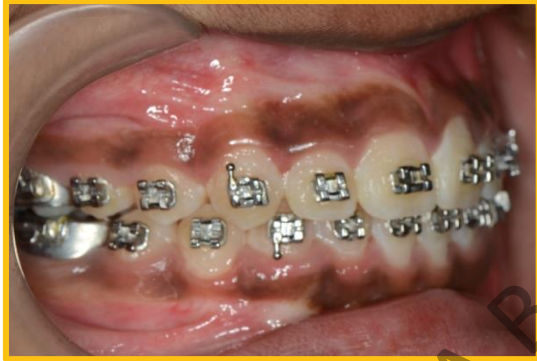PRE-TREATMENT



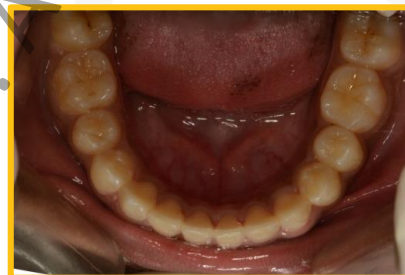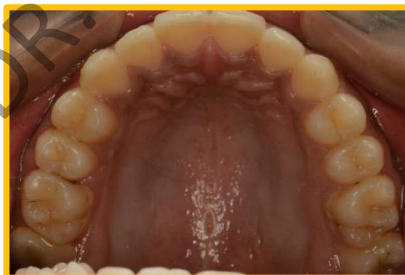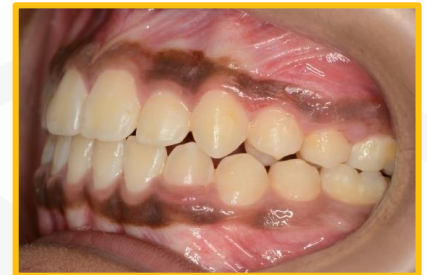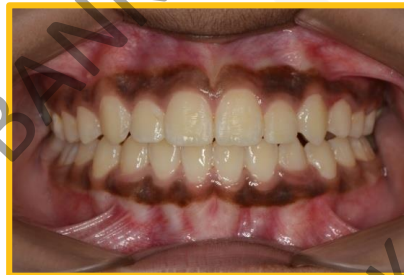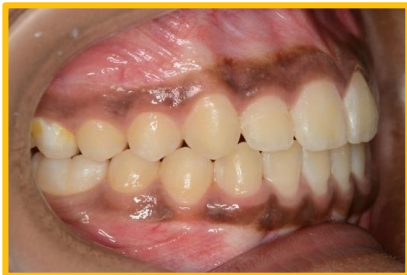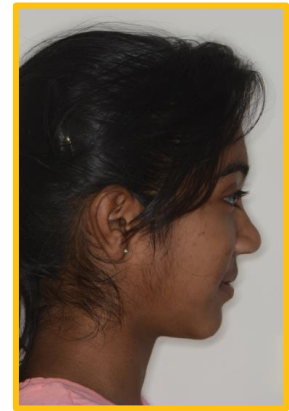
AFTER EXPANSION WITH SCREW PLATE



WITH FIXED APPLIANCE

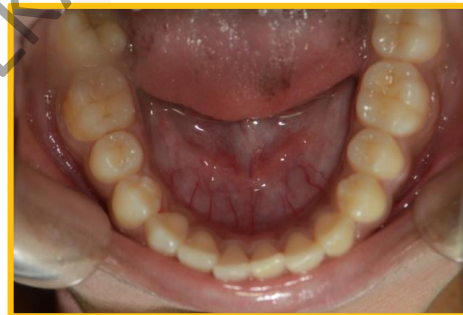
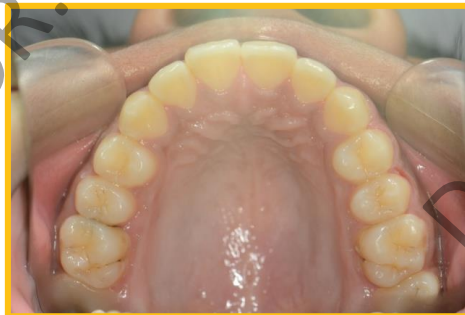
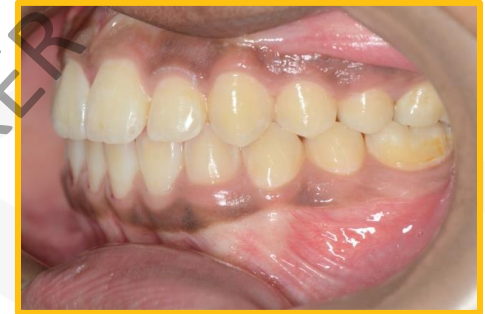
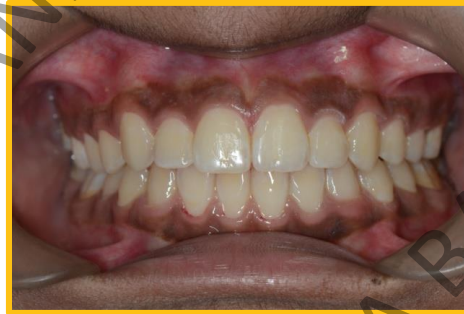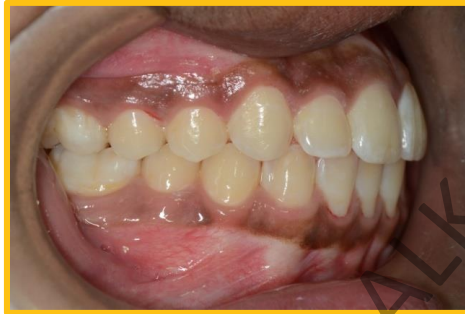POST TREATMENT



DR. ALKA BANKER

2 YEARS' FOLLOW UP



Isha a cute girl of age 9 years came to us with protruding teeth, crowding, Bunny smile, and a very narrow “v” shaped palate . We treated her with our modified appliance to broaden her palate & make space for her crowded uneven teeth. We then aligned her teeth and developed her smile with braces (MBT 0.022 Slot). Please note her BROAD , Beautiful smile, perfect parabolic arches and good gingival health & a very well balanced face even 2 years after treatment !



Treatments &
Case Studies

WWW.PULSEORTHODONTIA.COM